

<b>Patient ID</b>	28-05-2011-0001	<b>Visit Date</b>	2011-05-28
<b>Patient Name</b>	TEST	<b>LMP Date</b>	2010-10-10
<b>Age</b>	41	<b>Gestational Age</b>	32w 6d
<b>Sex</b>	Other	<b>Referred By</b>	




## OB - Third Trimester Scan Report

### Maternal Report


Type Of Scan : TA  
Cervix Details : 1.65 cm

### Fetus Report











#### Biometry(mm)

Measure	Value	Percentile	Gestational Age
Biparietal Diameter	58.4	 (<5%)	23w6d
Occipitofrontal Diameter	116.8		
Head Circumference	290.1	 (<5%)	32w0d
Anteroposterior Diameter	79.1		
Transverse Biparietal Diameter	82.9		
Abdominal Circumference	284.9	 (42%)	32w4d


#### EFW(grams)

Measure	Value	Percentile
BPD, AC	1232	 (<5%)

#### Longbones

Measure	Value	Percentile	Gestational Age
Tibia Right	55.8	 (72%)	34w0d
Tibia Left	55.8	 (72%)	34w0d
Fibula Right	28.5	 (<2%)	19w6d
Fibula Left	28.5	 (<2%)	19w6d
Humerus Right	56.2	 (55%)	33w3d
Humerus Left	56.2	 (55%)	33w3d
Radius Right	27.4	 (<2%)	20w3d
Radius Left	27.4	 (<2%)	20w3d
Ulna Right	51.2	 (12%)	30w5d
Ulna Left	51.2	 (12%)	30w5d

#### Aneuploidy Markers

Nasal Bone	9.5	 (23%)
------------	-----	---

Cephalic Index : 50 Dolicocephaly  
Transverse Cerebellar Diameter : 36.4 (13%)

#### Survey

AFI 2.11 + 2.08 + 2.04 + 1.86 = 8.089999  
Heart Rate 150 bpm

#### Fetal Anatomy

##### Head

Cisterna magna 20.3 X 20.3 mm

##### Face

Interocular Distance 23 mm

##### Thorax

Thoracic Circumference 247.8

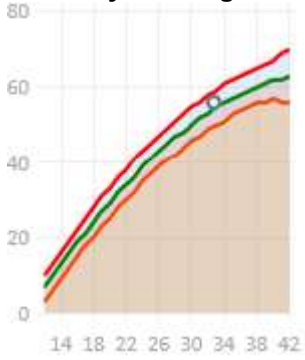
##### Other Biometries (mm/ms)

BOD 50.4

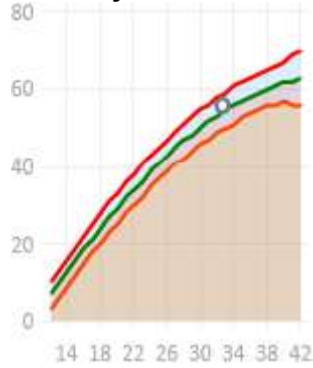
**Images**

**Growth Graphs**

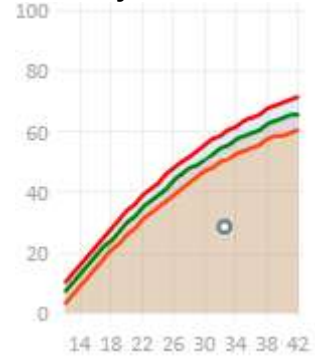
**Biometry TibiaRight**



**Biometry TibiaLeft**



**Biometry FibulaLeft**



**Impression**

*\*\* I declare that while conducting U.S.G. on this patient, I have neither detected nor disclosed the sex of fetus to anybody in any form.  
\*\*All anomalies cannot be detected on U.S.G.*

**Dr. Asha Joshi**