

Patient ID	25032414	Visit Date	2025-04-11
Patient Name	Mrs. TEST PATIENT	LMP Date	2026-03-15
Age	20	Gestational Age	10w -5d
Sex	Female	Referred By	Dr. test

OB - Early Trimester Scan Report

Maternal Report

Cervix Details : 3 cm
Cervix length is normal

Fetus Report

Biometry(mm)

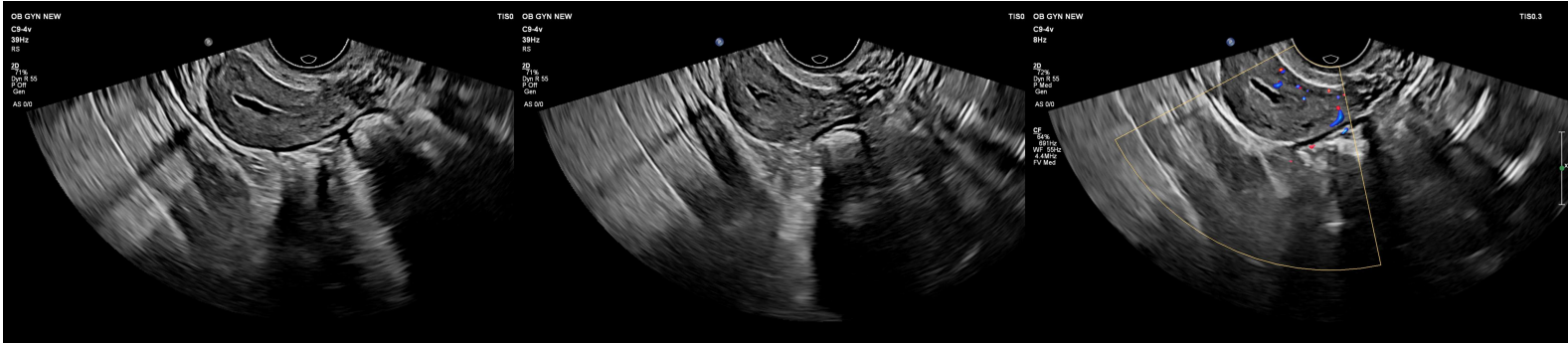
Measure	Value	Percentile	Gestational Age
Gestational sac diameter	32.0	(>97%)	9w2d
Crown-rump length	2.6	(>97%)	5w2d
Biparietal Diameter	32.0	(>95%)	15w6d

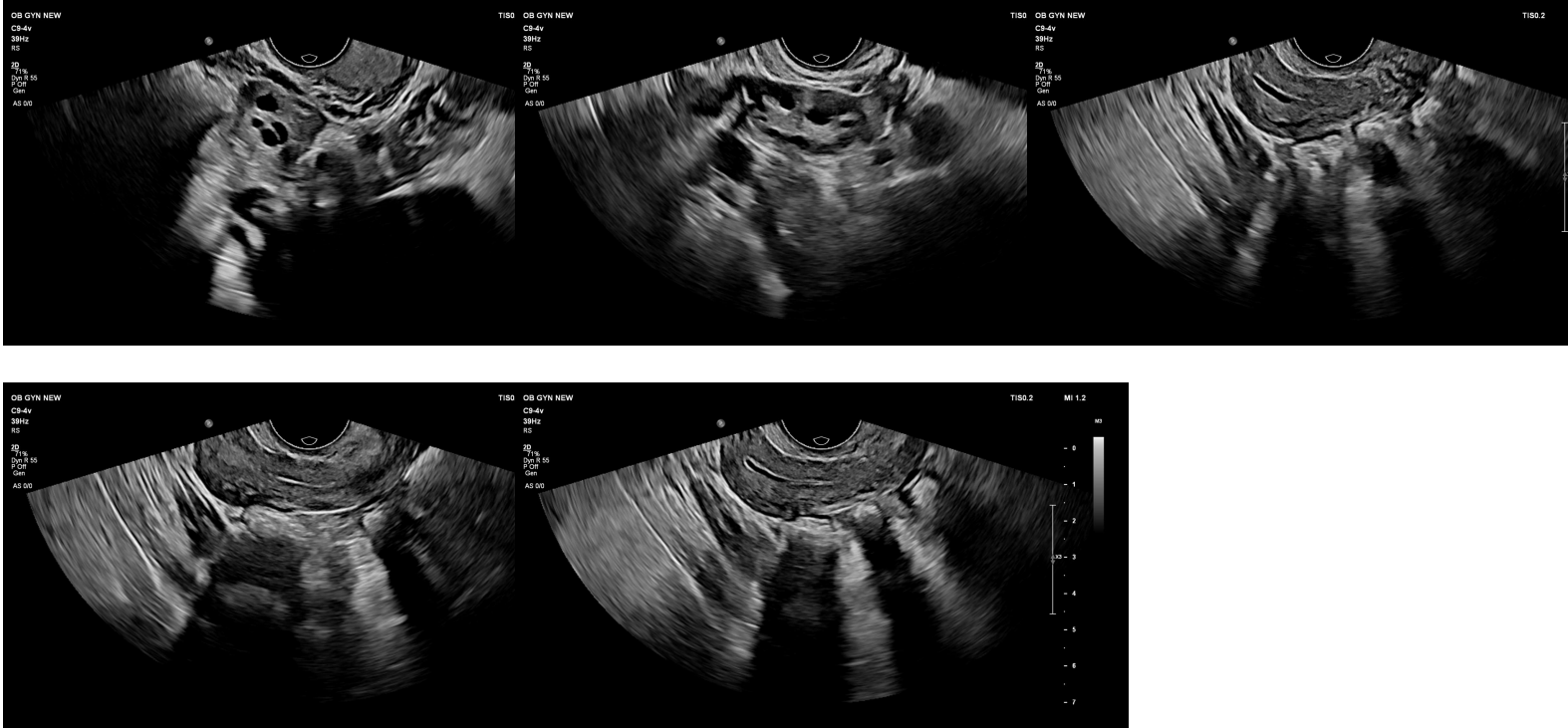
Comments : Measurements correspond to the 30th percentile for gestational age

Survey

Intrauterine Pregnancy	A single gestational sac is seen containing a yolk sac and/or an embryo with a positive fetal heart rate
Gestational Sac Description	Gestational Sac seen Sac margins appeared regular
Gestational Sac Comments	Gestational sac visualized
Embryo	Seen
Yolk Sac Description	Yolk sac seen
Yolk Sac Comments	Intrauterine gestational sac is seen with a normal yolk sac measuring 5.0 mm. No obvious abnormality noted. Correlate clinically for gestational age
Fetal Activity Description	Fetal activity present
Fetal Activity Comments	Single live intrauterine fetus visualized. Fetal movements are present and fetal cardiac activity is demonstrated.
Cardiac Activity Description	Cardiac activity present
Cardiac Activity Comments	Cardiac activity is visualized and appears normal
Heart Rate	145 bpm

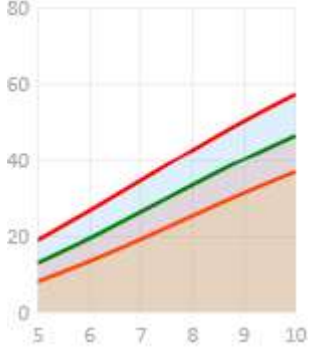
Images



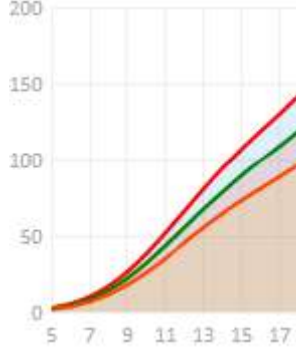


Growth Graphs

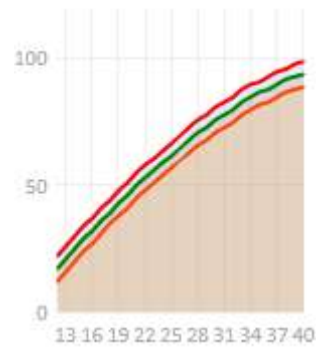
Biometry GSac



Biometry CRL



Biometry BPD



Impression

1 Live Fetus Of -53w -5d +/- 2 Weeks Of Gestational Age.

***All anomalies cannot be detected on U.S.G.*

test

**** I declare that while conducting U.S.G. on this patient, I have neither detected nor disclosed the sex of fetus to anybody in any form.**